


MISSION REPORT


KENYA

11 - 15 NOVEMBER 2024



Swiss⁺ABILITY

THE LARGE GROUP OF PARTICIPANTS FROM ACROSS ALL OF KENYA



Our final mission of 2024 was truly remarkable! Held in Nairobi, Kenya, we had the privilege of certifying 33 orthopedic technicians and donating 18 prostheses to amputees from both near and far.

We were graciously hosted by the **Kenya Medical Training College**, located next to the Kenyatta National Hospital, one of Africa's largest and most renowned medical centers. With 1'800 beds, over 6'000 staff members, and 50 departments, the hospital provided an ideal setting for our mission. The expansive space allowed our work to proceed smoothly and without interruption.

ORIENTATION

The introductory session began with a presentation of **SwissABILITY**, its objectives and ongoing projects. We then progressed to the main focus of the presentation, our “workhorse”, the **Monolimb**, the best performing and economical prosthesis in all of Africa. This technology aroused much enthusiasm, questions and discussions. Bernado Gomes lead the practical demonstration which held everyone’s attention. In combination with good organisation, we were able to aid **17 amputees**, of which one was a double amputee. * See Esther on page 7



INNOVATION AND PRACTICE

Tuesday was dedicated to the Alivio technology, with a hands-on demonstration led by **Peter**. This technology allows a transtibial prosthesis to be manufactured in just one hour, without the need for an orthopedic workshop. The “oven” used is a portable cylinder, ideal for mobile clinics or remote assistance programs, perfect for reaching communities in isolated or resource-poor areas.



THE HEART OF THE MATTER

The most profound moments of any mission often occur during direct interactions with the beneficiaries. It is during these encounters that we hear their stories—frequently heartbreaking, yet deeply moving. These narratives have a unique ability to teach us invaluable lessons in resilience and inner strength, humbling us in the process.

One such story that deeply moved us is that of **Blessing**, a 5-year-old boy who underwent a leg amputation at just six months old. His family, though profoundly affected by his trauma, demonstrated remarkable resilience, turning their pain into a powerful message of hope and inspiration.

Blessing is a self-assured little boy with an extraordinary ability to adapt. His zest for life inspires determination in everyone he meets. With the unwavering support of his family and the aid of a prosthesis, he confronts life's challenges head-on, embodying courage and resilience.

Read more of Blessing's story on page 7

Equally moving was Esther's testimony. She lost both her legs to a mysterious infection that led to severe gangrene. During the graduation ceremony, she took the microphone to express heartfelt gratitude to SwissABILITY and the technicians for her new prostheses. In a deeply touching gesture, she presented us with a **Certificate of Appreciation** on behalf of herself and all the other beneficiaries. It was the first time we had received such a meaningful recognition, making the moment even more unforgettable.



Esther (center in the red dress) presenting a certificate of thanks on behalf of herself and all the patients.

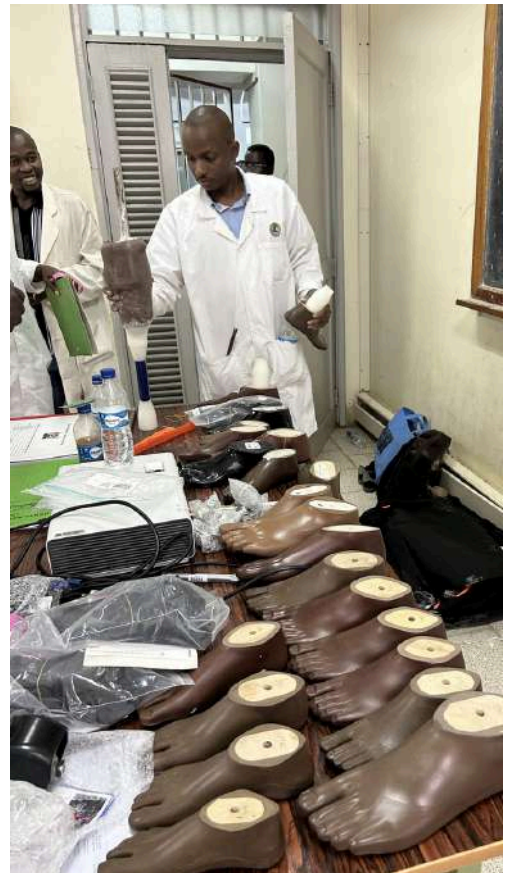WHILE IN THE WORKSHOP



Top left: Catherine, creating the positive of a model
Top right: Participants practising new skills



Some of the leaders making a difference in rehabilitation in Kenya



Feet lined up for attachment



Making the mould



Working on a Monolimb



The final products, ready for fitting

BENEFICIARIES

JAMES

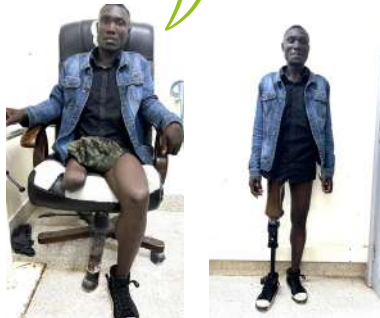47 years old, transtibial amputee due to a traffic accident



MONOLIMB PROSTHESIS

ERIC

29 years old, transfemoral amputee due to a congenital disorder



TRANSFEMORAL PROSTHESIS WITH ALL TERRAIN KNEE

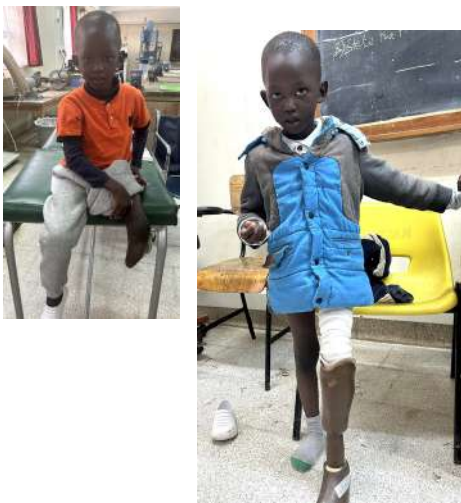FLORENCE

27 years old, transtibial amputee due to an accident



MONOLIMB PROSTHESIS

BLESSINGS'S STORY



MONOLIMB PROSTHESIS

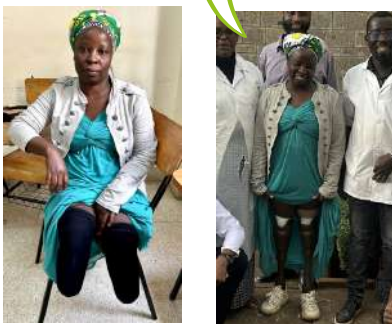When Blessing's mother realized that, in sharing her son's story, she had found someone who didn't merely view his situation as an accident but truly understood the depth of the tragedy he had endured, we shared a profound moment of connection and empathy.

Just five days after his birth, Blessing was diagnosed with hepatitis. The doctors quickly began treatment, administering medication through injections. However, just hours later, his tiny leg began to swell, and he started having convulsions. Days turned into weeks, and his condition continued to deteriorate. At six weeks old, doctors made the difficult decision to amputate Blessing's leg below the knee.

Despite his amputation, Blessing is a confident and talkative child who loves interacting with those around him. For him, his missing leg is little more than a minor inconvenience. Thanks to his new prosthesis, he can run, walk, and even climb trees—living freely and happily, just as any child his age should be.

ESTHER

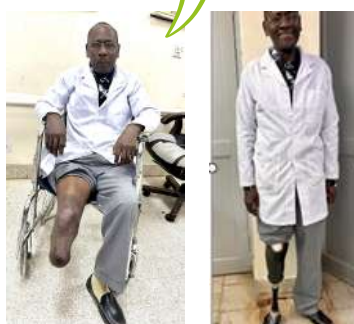45 year bilateral transtibial amputee due to gangrene



BI-LATERAL MONOLIMB PROSTHESES

JEREMIAH

62 year olds transtibial amputee due to diabetes



MODULAR PROSTHESIS WITH ALVIO TECHNOLOGY

JOHN

43 year old amputee after a physical assault

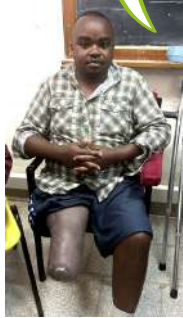

MODULAR PROSTHESIS

BENEFICIARIES

PETER H

33 years old, transtibial amputee due to a traffic accident



MONOLIMB PROSTHESIS (awaiting pickup)

NAFTALI

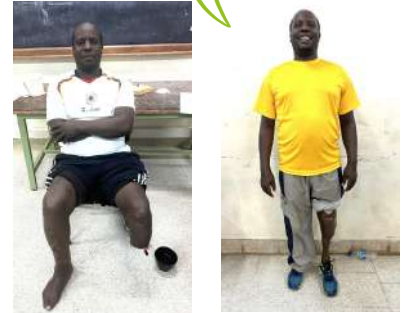33 years old, transtibial amputee due to a traffic accident



MONOLIMB PROSTHESIS

NICHOLAS

39 transtibial amputee due to a traffic accident

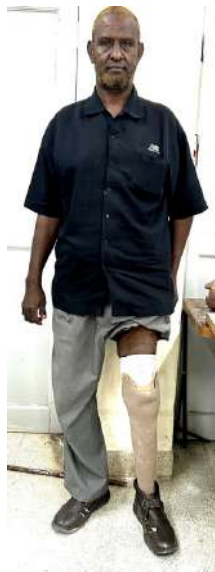

MONOLIMB PROSTHESIS

MOHAMMED'S STORY



MONOLIMB PROSTHESIS



In 1993, conflict erupted in Wajir County, a region in northeastern Kenya bordering Somalia and Ethiopia. The factions involved fought for control over territory, resources, and power. In just a few months, the brief yet intense violence claimed 1'200 lives and profoundly altered Mohammed's life and mobility.

"Our car hit an anti-vehicle mine. The explosion was deafening—utter chaos. When I regained consciousness, my leg was completely crushed. There was no saving it; they had to amputate," Mohammed recalls.

Since then, the 61 year old has relied on prostheses, but they were often heavy and prone to breaking. With the Monolimb prosthesis, however, Mohammed feels lighter and freer in his movements.

"Thank you, SwissABILITY!" he says with gratitude.

SALAASH

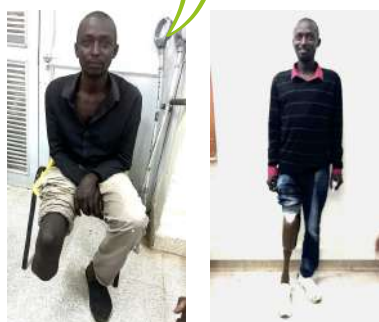31 years old, transfemoral amputee due to a road traffic accident



TRANSFEMORAL PROSTHESIS

ROBERT

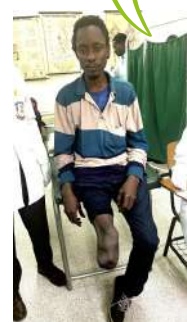34 years old, transtibial amputee due to an infection from a Tetanus injection



MONOLIMB PROSTHESIS

PETER N

35 years old, transtibial amputee due to an accident



MONOLIMB PROSTHESIS (awaiting pickup)

SAMSON

54 years old, transtibial amputee due to a road traffic accident



MONOLIMB PROSTHESIS

WINNY

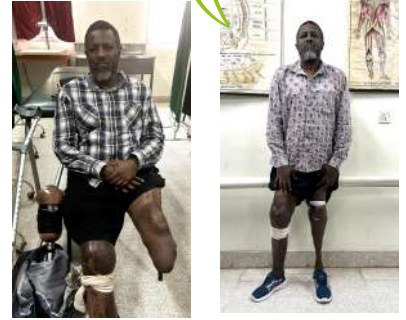28 years old, transtibial amputee due to a bloodclot



MODULAR PROSTHESIS

PATRIC

45 years old, transtibial amputee due to a road traffic accident



MONOLIMB PROSTHESIS

A GREAT GRADUATION

We concluded the mission with an event attended by **150 participants**, including amputees and their families, representatives of government ministries, college staff, the National Association of Ortho-Prosthetic Professionals, and all the technicians who participated in the mission. As you might imagine, there were numerous speeches, but the one that mean the most to us, was from the Head of National Rehabilitation of Kenya, **Alex Kysianga**, who extended an official invitation to SwissABILITY to continue its work and support in the country.



ACKNOWLEDGEMENTS AND FUTURE PROSPECTS

The future of SwissABILITY looks bright with a growing interest in the Monolimb and new calls for international collaborations.

A significant part of the success of this mission is owed to the tireless efforts of Bernardo Gomes, a skilled trainer who has been collaborating with SwissABILITY since 2016. His dedication, combined with the invaluable support of the team at Kenya Medical Training College (K.M.T.C.), the National Association of Orthopedic Technologists (N.A.O.T.), and their managers and staff, has been instrumental in achieving our goals.



Executive Director of SwissABILITY, Roberto Agosta and Technical Trainer, Bernardo Gomes were the two team members for this mission



Alex Kysianga, Head of National Rehabilitation of Kenya, with Roberto Agosta

We are deeply grateful to our valued donors, whose dedication and generosity make it possible for us to continue the vital and inspiring work of supporting the physical rehabilitation sector in Africa.

Thank you all! Together, we are building a better future.